Radiographic Evaluation of Single, Apex Down, Dorsal Metacarpal Stress Fractures Following Treatment with Extracorporeal Shockwave Therapy in 5 Thoroughbred Racehorses

Nathan D. Hein, DVM; Larry Metheney, DVM; Scott R. McClure, DVM,PhD

15404 Hollside Park Way, Cypress, TX 77433 (Hein); 19030 N. 22nd Street, Phoenix, AZ 85024 (Metheney); Department of Veterinary Clinical Sciences, College of Veterinary Medicine, Iowa State University, Ames, IA 50011 (McClure).

Thoroughbred racehorses treated with a single treatment of ESWT for dorsal cortical stress fractures were found to have shorter time to radiographic healing than rest alone and very similar time to radiographic closure as compared with surgical intervention.

1. Introduction

Extracorporeal shockwave therapy (ESWT) is becoming increasingly popular in the treatment of equine musculoskeletal injuries. Originally used in human medicine for the treatment of urolithiasis,[1,2] ESWT has evolved into a standard treatment option in many aspects of human and veterinary medicine. Today, ESWT is commonly used by many equine practitioners for the treatment of numerous orthopedic conditions including but not limited to injuries to the suspensory ligament,[3] tendonous injuries,[4] osteoarthritis of the distal tarsal joints,[5] navicular syndrome,[6,7] and dorsometacarpal disease in young thoroughbred racehorses.[8] However, even with the more recent advances in research, the effect of ESWT on equine bone and how it enhances healing is still relatively unknown.[6]

Dorsal cortical stress fractures are common occurrences in young thoroughbred racehorses while in training.[9-11] Previous reports have found stress fractures commonly occur in the middle portion of the dorsolateral cortex of MCIII in the left forelimb of 3-year-old Thoroughbred male racehorses.[12-15] Further work by Dallap showed stress fractures to be more prone to be single and consistently move in an apex down direction (dorsodistal to palmarproximal). Dorsal cortical stress fractures occur due to high strain cyclic loading of MCIII.[10,11,13,14] When the immature equine bone undergoing race training cannot adapt to these strain cycles, failure occurs in the form of dorsal cortical stress fractures.[16]

Traditional treatment options for dorsal cortical stress fractures include restricted exercise, surgical intervention, and radial shock wave therapy. Surgical treatments of stress fractures of MCIII have been extensively described and include transcortical screw fixation,[17] unicortical screw fixation,[18,19] osteostixis (cortical drilling),[20,21] and unicortical (positional) screw fixation combined with cortical drilling.[15] Recently, Palmar (2002) reported the use of RSWT in the treatment of 50 Thoroughbred racehorses afflicted with varying degrees of dorsometacarpal disease. RSWT is different from extracorporeal shock wave therapy in how the waves are generated and transmitted. While extracorporeal shock waves are generated outside the body and

focused at a specific site, radial shock waves are generated from a projectile mechanism and are transmitted radially, decreasing in energy proportional to the square of the distance from the surface.[22] Horses in Palmar's study using RSWT were out of training for a minimum of 8 weeks and had undergone other treatment protocols (i.e. rest, osteostixis, etc) before undergoing first treatment with RSWT.[8] The purpose of this study was to evaluate the effectiveness of a single treatment with ESWT in the treatment of dorsal cortical stress fractures when compared to surgical intervention and restricted exercise.

2. Materials and Methods

Horses included in the study had an acute, single, apex down, dorsometacarpal stress fracture. Cases were deemed acute if injury incurred within one week of evaluation and if radiographs had no evidence of exostosis or callus formation around fracture site. Five horses were included in the study. Within one week of incurring the radiographically confirmed stress fracture, all cases were scheduled for shockwave therapy. Post-treatment evaluations were scheduled at two-week intervals starting at 4 weeks post-treatment. The evaluations consisted of a physical examination, a brief lameness evaluation using definition and classification approved by the AAEP, and radiographs of the fracture site. Radiography of the afflicted metacarpus included taking four views that included a lateromedial, dorsopalmar, 45-degree dorsolateral-palmarmedial oblique (DLPMO), and a 45-degree dorsomedial-palmarlateral oblique (DMPLO). All radiographs were taken using the same technique. Post-treatment evaluations were scheduled to continue until the fracture was no longer evident on all radiographic views.

Shockwave therapy was performed with horse standing under mild sedation with detomidine HCL[a] (.02 mg/kg IV) and butorphanol tartrate[b] (.02 mg/kg IV) for treatment. Physical restraint with a lip chain was also used. The dorsal aspect of the left metacarpus was clipped with a #40 clipper blade from the carpometacarpal joint distally to the metacarpophalangeal joint. The clipped area was then wiped using alcohol soaked gauze to remove debris from treatment area. Contact gel was then placed on the treatment area and shockwave therapy was initiated using VersaTron®[c] 5mm probe. Treatment regimen consisted of administering a total of 1,000 pulses at the E6 energy level. An attempt was made to focus 500 of the pulses directly at fracture location with the remaining pulses directed over the entire dorsal cortex.

Following shockwave therapy, isopropryl alcohol was sprayed over the clipped area and leg was wrapped with a cotton support bandage. In each case, the trainer was advised to spray treated area with isopropryl alcohol and to maintain cotton bandages on the legs for two days. Rehabilitation after ESWT included two weeks of stall rest followed by two weeks of stall rest with walking (by hand or on a walker). Provided no lameness was present at time of first radiographic follow-up and radiographic evidence of fracture healing was evident, horse was then allowed small paddock turnout. Owners were encouraged to begin swimming after 2 months post treatment and a gradual return to training was allowed after radiographic evidence of fracture closure.

3. **Results**

Five Thoroughbred racehorses (4 males and 1 female) met the criteria to be included in this study. All horses were referred with acute history of lameness following workout or race. The mean age of horses in this study was 2.8 years-old with a range of 2-4 years-old. All 5 horses in this study had single, apex down (DDPP), dorsal cortical stress fractures with lesions solely in the left forelimb (**Fig 1**). Mean cortical involvement was 45% with a range of 20-65%. The mean lameness grade at time of the first treatment with ESWT was 2.2 with a range of 1-3 (AAEP scale of 1-5). Radiographic evaluation at 4 weeks post-shock wave treatment showed increase in fracture width in all 5 horses (**Fig 2**). Horses in this case series were found to have radiographic closure of fracture in an average of 73 days (2.4 months) post-shock wave therapy (**Fig 3**). No complications were seen following any treatments or reported by trainers or owners at any of the follow-up examinations in any of the horses treated.

Figure 1— DMPLO of the dorsolateral cortex of MCIII in Case 1 with dorsal cortical stress fracture. Radiograph was taken 4 days after horse became acutely lame after morning workout.

Figure 2— DMPLO of the dorsolateral cortex of MCIII in Case 1 with dorsal cortical stress fracture. Radiograph was taken 4 weeks post-shockwave therapy. Notice fracture width has increased since initial injury.

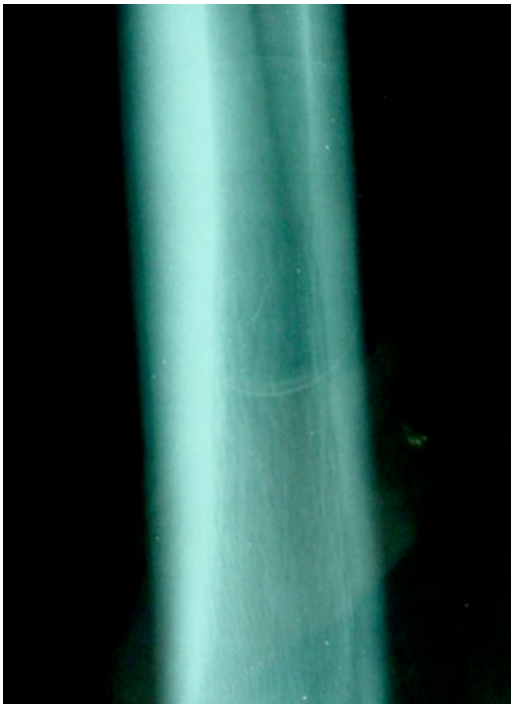

Figure 3— DMPLO of the dorsolateral cortex of MCIII in Case 1 with dorsal cortical stress fracture. Radiograph was taken 10 weeks post-shockwave therapy showing intact cortex and no signs of previous stress fracture.

4. Discussion

Conservative treatment consisting of 7 months of restricted exercise for dorsal cortical stress fractures is related to an unfavorable outcome.[23] Surgical treatments described include transcortical screw fixation,[17] unicortical screw fixation,[18,19] osteostixis (cortical drilling),[20,21] and unicortical (positional) screw fixation combined with cortical drilling.[15] Before recent advent of shockwave therapy, surgical intervention was treatment of choice. It was hypothesized in previous work that cortical drilling had numerous effects on the response of equine bone that included improving the vascular supply to the fracture and in turn stimulating osteogenesis by bringing osteoblasts to the fracture gap.[24] Further benefits included creating a stress-concentrating effect, thus stimulating bone remodeling.[15] Addition of screw placement in many studies is due to the significant osteonal response it creates due to the difference in elastic modulus of screw and surrounding bone.[25] Recently, Palmar (2002) reported the successful use of radial shock wave therapy in the treatment of 50 Thoroughbred racehorses afflicted with varying degrees of dorsometacarpal disease. However, horses in this study were out of training for a minimum of 8 weeks and had been treated with various other treatment protocols (i.e. rest, osteostixis, etc) before undergoing first treatment with RSWT.

In all cases in this series, only acute, single, apex down stress fractures were treated. Only one treatment of shockwave therapy was used in all cases. Sequential radiographic follow-up demonstrated increase of fracture gap between initial radiographs and 4-week follow-up radiograph in all cases. This was believed to be due to increased osteoclastic activity in the area and remodeling associated with normal fracture healing. This increased fracture width was not seen in any of the following radiographs. In all cases sequential radiographs showed an increase in opacity in fracture gaps at varying rates that corresponded with initial fracture length and initial cortical involvement. Horses in this case series were found to radiographic closure of fracture in an average of 73 days (2.4 months) post-shock wave therapy. This interval is substantially shorter than non-surgical management alone and very similar to surgical treatment with osteostixis and unicortical screw fixation. It was found that stress fractures in horses treated with 7 months of restricted exercise may or may not be radiographically healed after this time frame.[23] While horses with a single left front stress fracture treated surgically resulted in median time to screw removal being 2.0 months with 39/41 horses being declared radiographically healed.[15]

No complications were seen following any treatments or reported by trainers or owners at any of the follow-up examinations in any of the horses treated. Apart from avoiding the risks associated with general anesthesia, the advantages of ESWT over surgical intervention include: a decrease in patient morbidity, performed as an outpatient procedure, less invasive than surgical treatment, avoidance of surgical complications such as incisional infections, broken drill bits left in MCIII, catastrophic failure of MCIII,[15,16,21] and being more cost-effective than surgery.

We conclude Thoroughbred racehorses treated with single treatment of ESWT for dorsal cortical stress fractures were found to have a shorter time to radiographic healing than rest alone and very similar time to radiographic closure as compared with surgical intervention. It is acknowledged that, although preliminary results are encouraging, more cases should be evaluated to asses whether the prognosis for returning to training and racing is better when using ESWT than previously reported treatment modalities.

5. References and footnote

1. Adams LG, Senior DF. Electrohydraulic and extracorporeal shock wave lithotripsy. *Vet Clin North AM: Small Anim Pract*. 1999;29:293-302.

2. Pettersson B, Tiselius HG. Extracorporeal shock wave lithotripsy of proximal and distal ureteral stones. *Eur Urol* 1988;14:184-188.

3. McClure SR, VanSickle D, White RM. Effects of Extracorporeal Shock Wave Therapy on Bone. *Vet Surg* 2004;33:40-48.

4. Kersh KD, McClure SR, Evans RB, Moran L. Ultrasonagraphic Evaluation of Extracorporeal Shock Wave Therapy on Collagenase-Induced Superficial Digital Flexor Tendonitis, in *Proceedings*. Am Assoc Equine Pract 2004;50:257-260.

5. McCarroll GD, McClure SR. Initial experiences with extracorporeal shock wave therapy for treatment of bone spavin in horses – part II. *Vet Comp Orthop Traumatol* 2002;15:184-186.

6. McClure SR, VanSickle D, Evans R, Reinerstson, EL, Moran L. (2004b) The effects of extracorporeal shock-wave therapy on the ultrasonagraphic and histologic appearance of collagenase-induced equine forelimb suspensory ligament desmitis. *Ultrasound Med Bio* 2004;4:461-467.

7. McClure SR, Evans RB, Miles KG, et al. Extracorporeal Shockwave Therapy for Treatment of Navicular Syndrome,in *Proceedings*. Am Assoc Equine Pract 2004; 50:316-319.

8. Palmer SE. Treatment of Dorsal Metacarpal Disease in Thoroughbred Racehorses with Radial Extracorporeal Shock Wave Therapy., in *Proceedings*. Am Assoc Equine Practnr 2002;48:318-321.

9. Stashak TS. The metacarpus and metatarsus.Periostitis and fracture of the the dorsal metacarpus (bucked shins, shin splints, and stress fracture). In: Stashak TS, ed. *Adams' lameness in horses 4th ed*. Philadelphia: Lea and Febiger, 1987;596-601.

10. Nunamaker DM, Butterweck, DM, Provost MT. Fatigue fractures in thoroughbred: Relationships with age, peak bone strain and training. *J Orthop Res* 1990;8:604-611.

11. Nunamaker DM. Metacarpal Stress Fractures. In: Nixon AJ, ed. *Equine Fracture Repair, 1st ed.* Philadelphia: WB Saunders, 1996:195-199.

12. Sullins KE. Drilling of dorsal metacarpal stress fractures: Technique in the standing horse, in *Proceedings*. Am Assoc Equine Pract 1989;35:333-339.

13. Nunamaker DM. The bucked shin complex, in *Proceedings*. Am Assoc Equine Pract 1982;32:457-460.

14. Nunamaker DM, Butterweck D.M, Black J. In vitro comparison of Thoroughbred and Standardbred racehorses with regard to local fatigue failure of third metacarpal bone. *Am J Vet Res* 1991;52:97-100.

15. Dallap BL, Bramlage LR, Embertson RM. Results of screw fixation combine with cortical drilling for treatment of dorsal cortical stress fractures of the third metacarpal bone in 56 Thoroughbred racehorses. *Equine Vet J* 1999;31:252-257.

16. Hanie EA, Sullins KE, and White NA. Follow-up of 28 horses with third metacarpal unicortical stress fractures following treatment with osteostixis. *Equine Vet J Suppl,* II 1992;24:4-9.

17. Norwood GL. The bucked shin complex in Thoroughbreds, in *Proceedings.* Am Assoc Equine Pract 1978;24:319-336.

18. Copelan RW. Incidence, location and principles of treatment of stress fractures of the third metacarpal bone, in *Proceedings*. Am Assoc Equine Pract 1979;25:159-162.

19. Collier MA, Rendano VT, Kallfelz FA. Repair of a delayed-union stress fracture of the dorsal cortex of a metacarpal bone in a horse. J Am Vet Med Assoc 1985;187:1040-1043.

20. Specht TE, Clahan PT. Osteostixis for incomplete cortical fracture of the third metacarpal bone. Results in 11 horses. *Vet Surg* 1990;19:34-40.

21. Cervantes C, Madison JB, Ackerman N, Reed WO. Surgical treatment of dorsal cortical fractures of the third metacarpal bone in Thoroughbred racehorses: 53 cases (1985-1989). *J Am Vet Med Assoc* 1992;200:1997-2000.

22. Pauwels FT, McClure SR, Amin V, et al. Effects of extracorporeal shock wave therapy and radial pressure wave therapy on elasticity and microstructure of equine cortical bone. *Am J Vet Res* 2004;65:207-212.

23. Richardson DW. Dorsal cortical fractures of the equine metacarpus. *Comp Cont Educ Pract Vet* 1984;6:S248-S255.

24. Williams JGP. Recalcitrant stress fracture: a caase managed by drilling. *Br J Sports Med* 1979;13:84-85.

25. Martin RB. Osteonal remodeling in response to screw implantationin Canine Femora. *J Orthopead Res* 1987;5:445-452.

a Dormosedan®, Orion Corporation, Espoo, Finland
b Torbegesic®, Fort Dodge Animal Health, Fort Dodge, IA 50501.
c Versatron®, High Medical technologies, Inc., Kenesaw, GA 30144